

Endovascular Stent Reconstruction for Recurrent Superior Vena Cava Syndrome in a Dialysis-Dependent Patient

Logan Broome, MD

Cleveland Clinic Florida

Department of Vascular Medicine and Surgery

Disclosures

- No financial conflicts of interest
- The use of the Gore Excluder cuff endoprosthesis in this case represents off-label device use



Background

- Central venous stenosis and obstruction are well recognized complications in long-term hemodialysis access patients
- Recurrent stenosis following balloon angioplasty is common
- Preserving dialysis access is critical



Objectives

- To describe endovascular reconstruction of recurrent SVC obstruction using large-diameter cuff endoprotheses in a complex dialysis-dependent patient



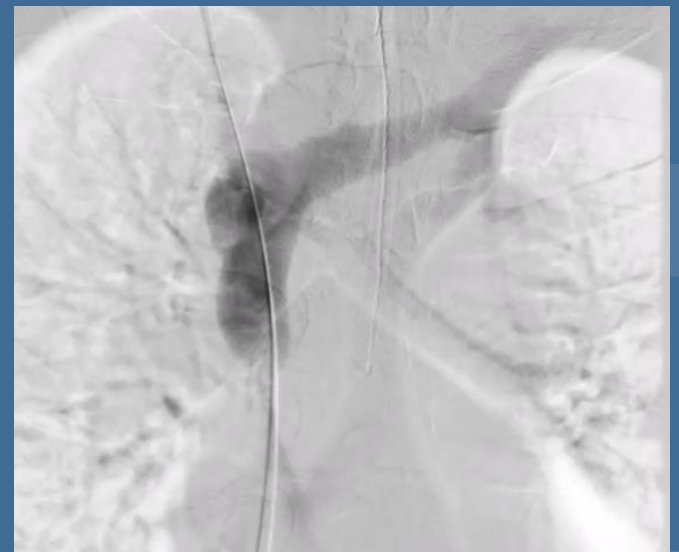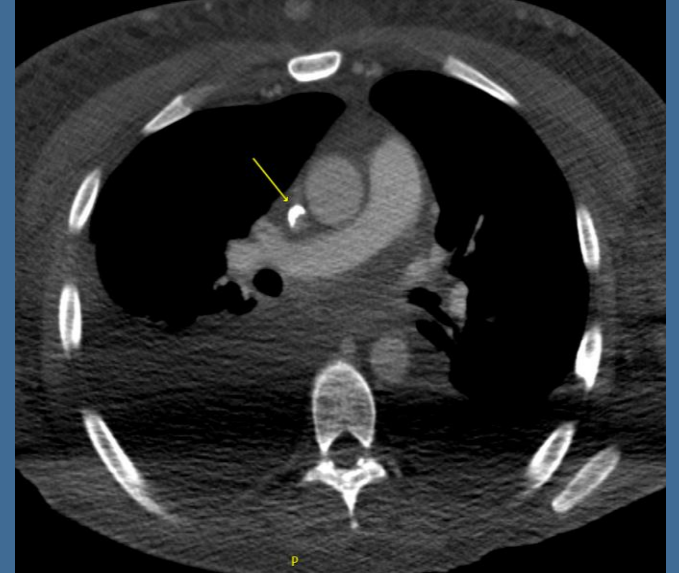Clinical History

- 33-year-old male
- ESRD
- Failed renal transplant
- RUE AV Fistula with aneurysmal degeneration
- SVC stenosis with prior SVC balloon angioplasty
- On apixaban



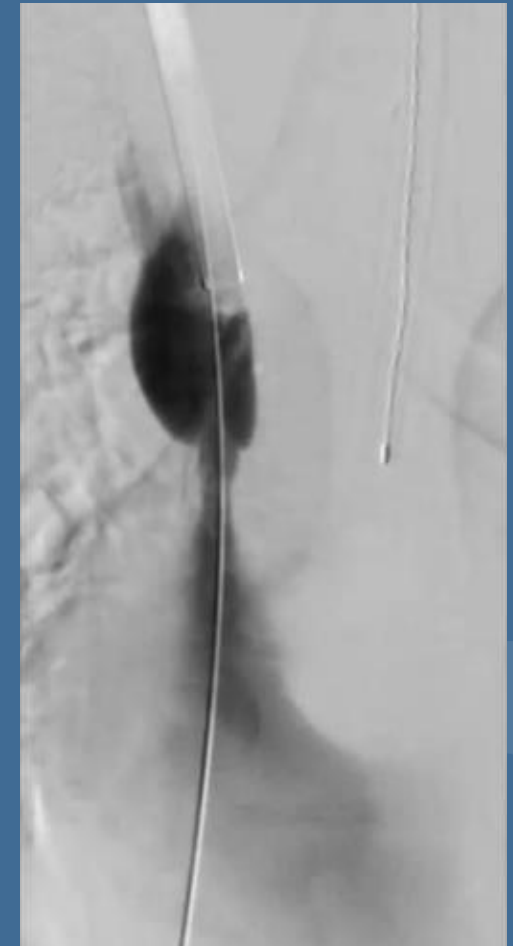
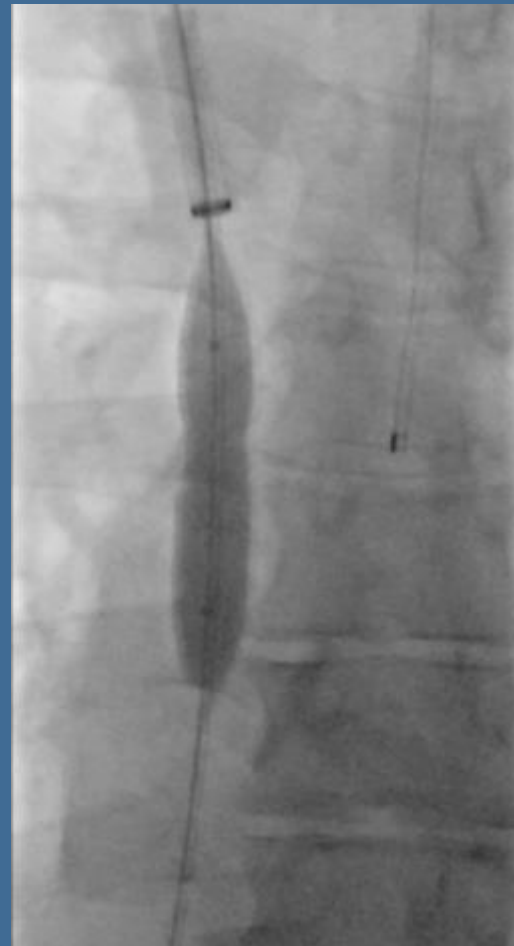
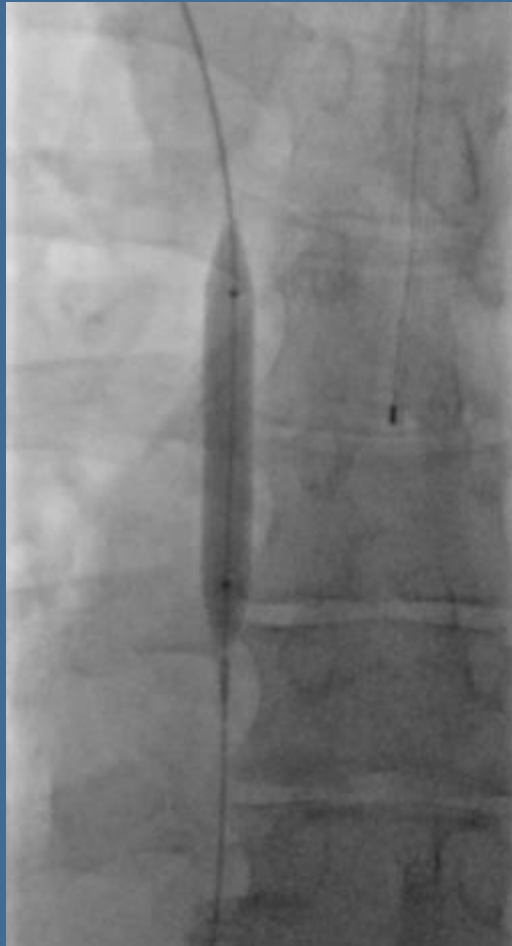
Presentation

- Progressive neck + R arm swelling for 2 days
- Excessive bleeding of AVF following dialysis
- CT: Recurrent severe SVC stenosis with extensive collaterals
- Venogram confirmed SVC stenosis



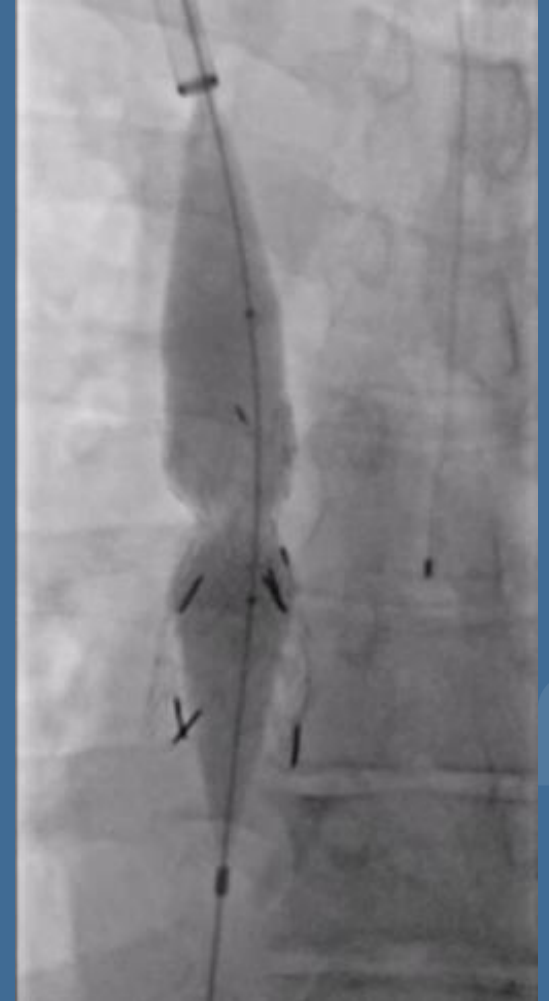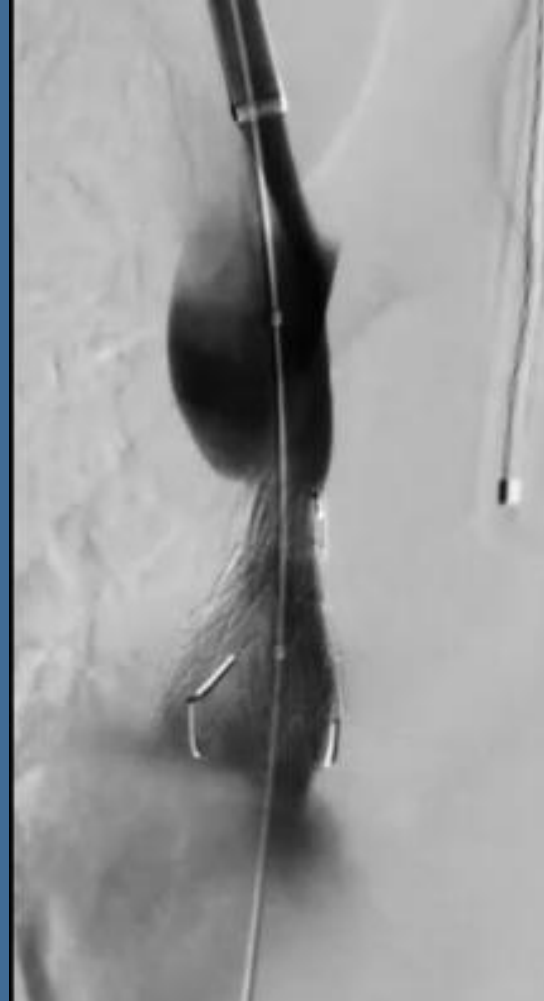
Endovascular Intervention

- Lesion traversed
- Sequential angioplasty (8 to 12 mm)
- Resulted in 70% residual stenosis



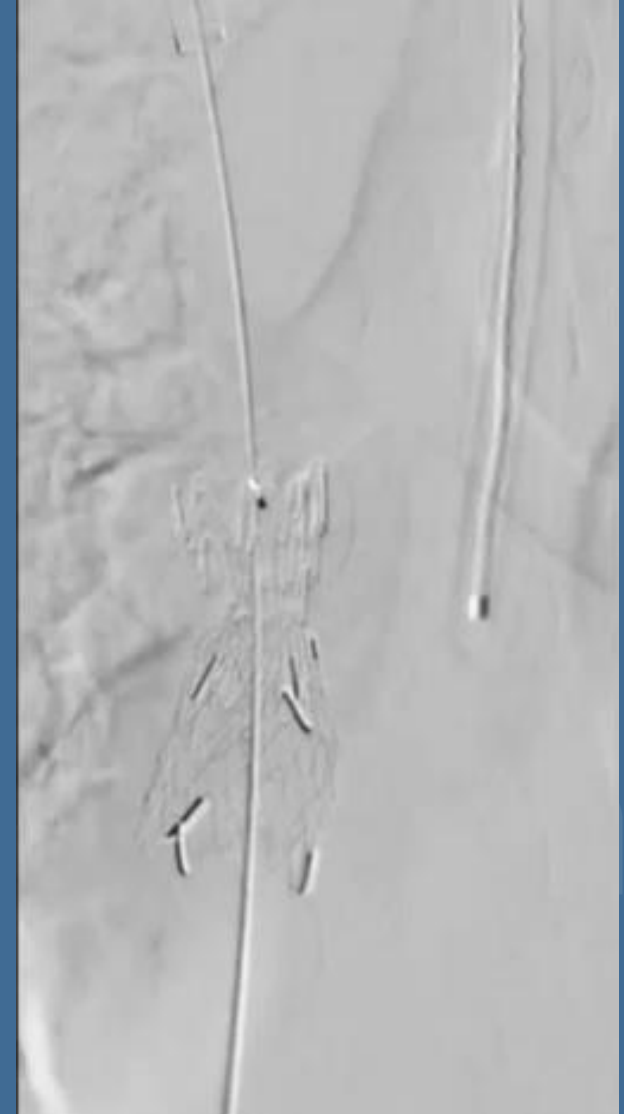Endovascular Intervention

- Deployment of two GoreExcluder cuffs (23×33, 26×33mm)
- Post-dilation with 18 mm Atlas balloon



Results

- Brisk antegrade flow
- Less than 40% residual narrowing
- No rupture, migration, bleeding
- Dialysis uninterrupted
- Complete symptom resolution at 2 weeks



Conclusion

- Balloon angioplasty alone often fails in recurrent central venous disease
- Large-diameter cuff endoprotheses offer:
 - Radial strength
 - Controlled expansion
 - Reduced rupture risk vs aggressive ballooning alone





Every life deserves world class care.

